

# Pierre Robin and the Syndrome That Bears His Name

PETER RANDALL, M.D.  
WILTON M. KROGMAN, Ph.D.  
SOONA JAHINA, B.D.S., M.Sc.  
*Philadelphia, Pennsylvania*

The Pierre Robin Syndrome refers to a combination of micrognathia (a small jaw) and glossoptosis (literally, a falling downward or backward of the tongue) in the newborn infant (Figure 1). These conditions are likely to cause obstruction of the upper airway, and they are frequently associated with an incomplete cleft of the palate.

Patients with the Pierre Robin Syndrome may present a real emergency in the delivery room because of the obstructed upper airway, or the airway problem may not become manifest for several days or weeks (10, 11, 38). There is frequently a feeding problem, as well as problems associated with the cleft of the palate (if one is present) and also an unusual malocclusion (2, 5, 12, 16). In addition, it presents a fascinating anthropological puzzle (22, 23). This paper will review the work of Dr. Robin, consider some possible etiologies of this syndrome, and report on some work on mandibular bone growth in a group of such patients.

## History

Pierre Robin was far from the first person to recognize this syndrome. One account is recorded in 1822 by St. Hilaire. In 1891 Taruffi mentioned two subclassifications—hypomicrognathus (small jaw) and hypognathus (absent jaw). In 1891, four cases, two of them having cleft palates, were reported by Lanneloague and Monard (12, 14). Shukowsky in 1902 described a tongue to lip surgical adhesion to overcome the respiratory obstruction (34). However, Robin deserves credit for calling attention to the condition, and for pointing out some of the grave dangers that may accompany it (24, 25, 26, 27, 30, 31).

Robin was a French stomatologist. He was born in 1867 and died in 1949. He was a professor in the French School of Stomatology as well as Editor of the periodical *Stomatologie*. He wrote his doctoral thesis

---

Presented at the 1964 Convention of the American Cleft Palate Association, Los Angeles, California.

Drs. Randall, Krogman, and Jahina are affiliated with the Children's Hospital Cleft Palate Clinic, the Philadelphia Center for Research and Child Growth, and the Harrison Department of Surgical Research, the University of Pennsylvania Schools of Medicine.

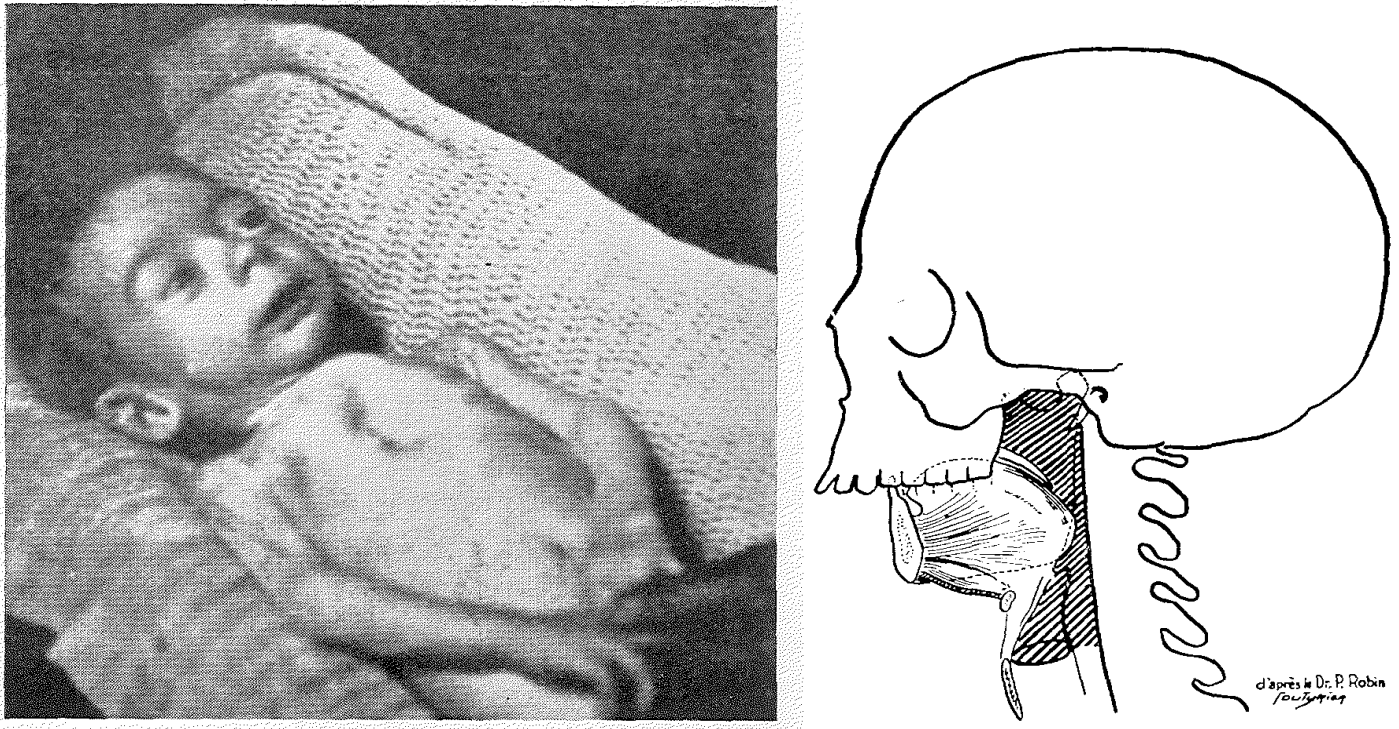


FIGURE 1. These are two illustrations from a monograph by Pierre Robin. On the left an infant is seen with micrognathia and glossoptosis producing respiratory obstruction. The severe retraction of the sternum is easily seen, and the child is quite emaciated. On the right Dr. Robin shows diagrammatically how the posterior displacement of the mandible allows the tongue to fall against the posterior wall of the oral pharynx causing a ball valve type of obstruction. These findings may or may not be associated with an incomplete cleft of the palate. From Robin (24).

on the role of mastication and the follicular sac on the eruption of teeth, and he even described an expansion prosthesis with a turnbuckle which is very similar to the type advocated today (21, 32). In 1923 he published the first of approximately 17 articles on the problems of glossoptosis, and said that he treated this condition with a 'monobloc', which he first described in 1902 and which was used to restore the normal relationship between the upper and lower jaw. In 1929 he published a monograph on the subject.

Robin described the feeding problems typically presented by such children and their difficulties with failure to gain weight. He also said that glossoptosis could be the cause of cyanosis and pulmonary infection. In severe cases he noted that death was inevitable and he wrote, 'I have never seen a child live more than 16 to 18 months who presented hypoplasia such as the lower maxilla was pushed more than 1 cm behind the upper' (29).

Unfortunately, he became quite carried away by his findings and stated further that this condition occurs in three out of five babies, and that it could predispose to 'protruding ears, kyphosis, scoliosis, lordosis, strabismus, adenoids, carious teeth, flat feet, harelip, rachitic rosary,

# GRANDS SYNDROMES DU GLOSSOPTOSISME

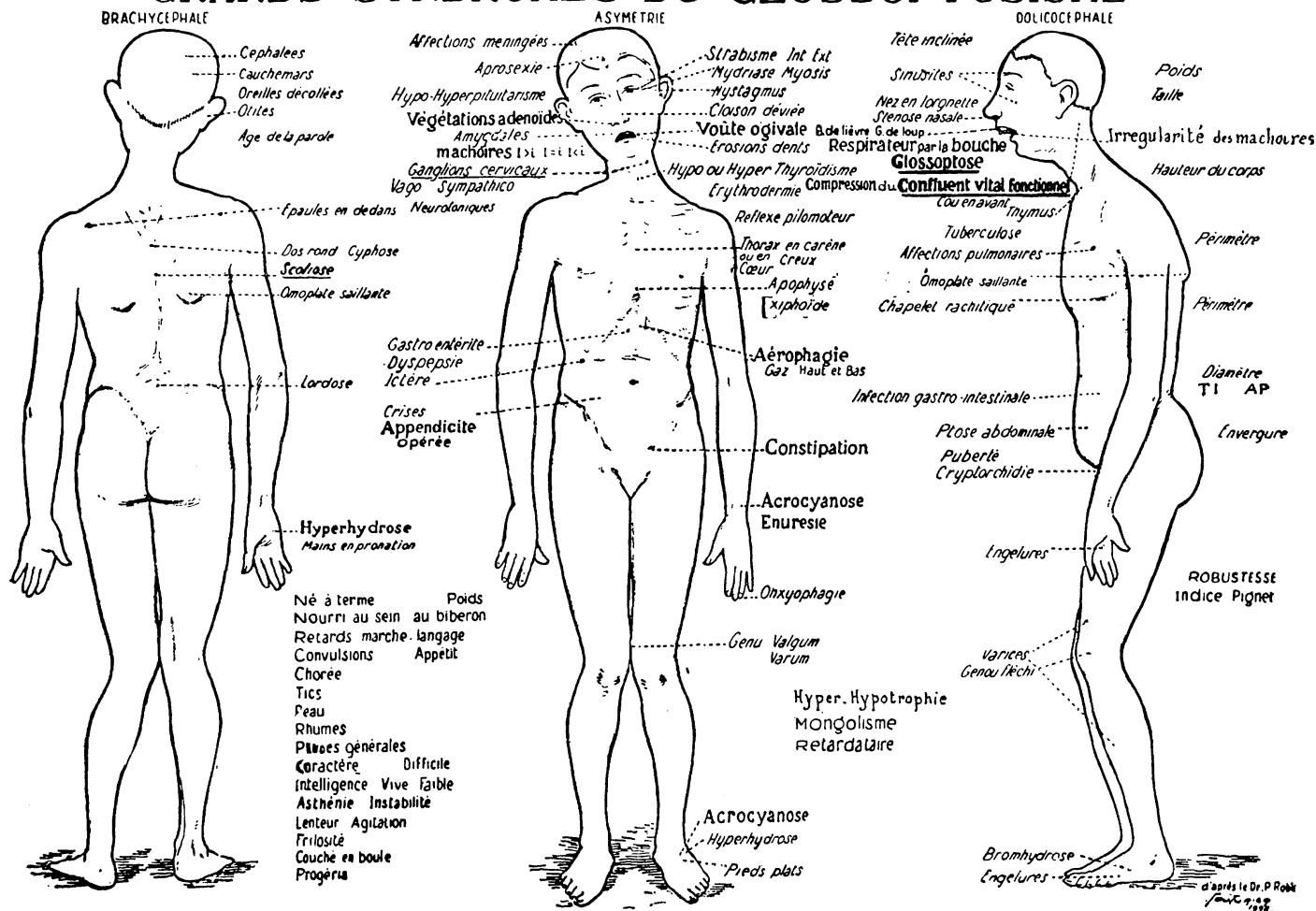


FIGURE 2. Pierre Robin deserves credit for calling attention to this syndrome and the dangers that might develop. However, in his enthusiasm he became quite carried away and felt that the condition could predispose to a few other problems as well, as noted above. From Robin (24).

cryptorchidism . . . appendicitis, constipation, and enuresis' (28). He described a cleft palate in one of his patients (Figure 2).

## Etiology

The exact cause of this condition is not known and in all likelihood there is no single etiology. A possible hereditary factor has been pointed out by several authors, but in larger series this has not been a striking factor (4, 13, 14, 15, 17). In 1955 Chappel wrote that

... the structures involved arise from different anlagen, from different layers at different times. A single gene covering this odd assortment has no parallel. The structures are in no other way related, to our knowledge, but by their mechanical relationship where the one can so readily affect the other. (?)

Several authors had mentioned the possibility of intrauterine pressure

being a factor, and Chappel further pointed out that 'the position of comfort', noted by Parmalee as indicating the likely intrauterine position, could be applied to babies with this deformity. In this syndrome the head would be sharply flexed on the chest with the chin pushed up behind the manubrium (6, 7, 8, 9, 18, 20, 36). During fetal development, if the head did not raise at the cephalic flexure at the proper time, the tongue would be positioned between the folds of the soft palate and prevent their natural union. Indeed, in the newborn this is often the situation, and the tongue can be seen displaced up into the nasopharynx well above the level of the soft palate (3, 6, 7, 8, 12).

In 1934 Robin wrote the following:

Mandibular hypotrophy is never idiopathic. As a rule it is caused by congenital syphilis or tuberculosis, by hereditary dystrophia from alcoholism or by some other infection. Occasionally, a mild case occurs in the child of parents, one of whom has large jaws, and the other, narrow ones. The child has a broad upper jaw and a narrow lower one or vice versa, so that there is a lack of equilibrium between the two and functional troubles appear. (29)

### **Bone Growth**

Twenty-two patients were studied by roentgenographic cephalometric examination at various ages. All of these patients had clinical micrognathia in the neonatal period with mild to severe respiratory obstruction. The micrognathia was confirmed by x-ray examination, either in the first year of life or shortly thereafter. All of these patients also had clefts of the soft palate with or without extension into the posterior portion of the hard palate (23).

The Sassouni proportional method of roentgenographic cephalometric analysis based on cranio-facial relationships was used (33). This method of analysis relates the size of one part of the facial architecture to the other facial bones in any given patient so that it is possible to determine whether the mandible, for example, is of relatively normal size or whether it is out of proportion in comparison with the other facial structures. In addition, facial structures are related to the cranial base and actual measurements can also be made to compare the size of these structures with accepted normal values.

Studies made on 18 of these patients at about one year of age were compared with 112 studies on normal patients at comparable ages and the findings showed that only two-thirds of the cases with Pierre Robin Syndrome were truly micrognathic. There were, however, a number of other measurements that varied from the norms. The length of the cranial base and the degree of the cranial base angle showed the greatest discrepancies. The gonial angle also varied depending somewhat on the size of the mandibular corpus, which tended to be more obtuse in those mandibles with small corpal length.

Study of the subsequent growth of these mandibles showed three well-

defined patterns of growth and also a group of miscellaneous patterns (Figures 3 and 4).

One group of patients eventually showed an almost normal size and position of the mandible. This is illustrated in Figure 5 (top). This

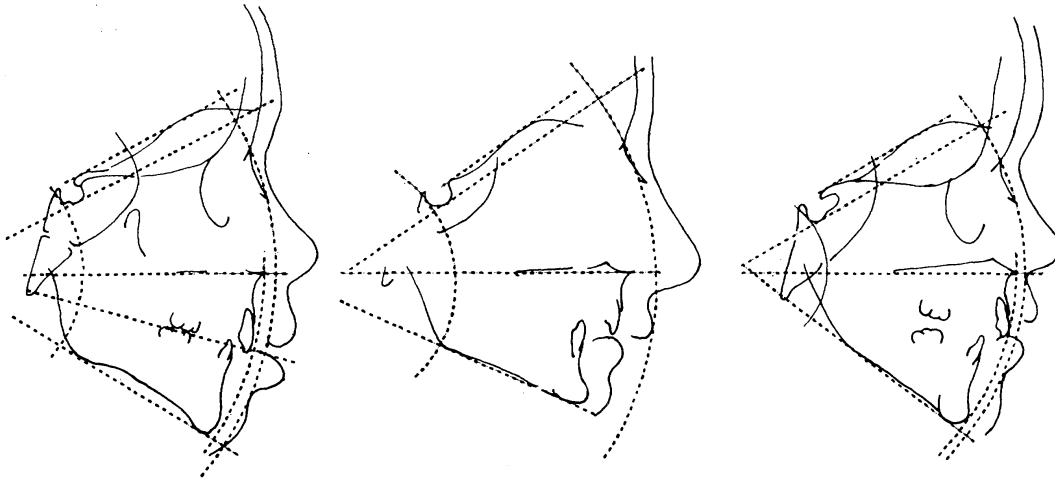


FIGURE 3. The subsequent mandibular growth seen in 18 patients studied by roentgenographic cephalometric analysis fell into three well-defined groups illustrated above, plus a miscellaneous group mentioned in the text. *Left.* Three patients showed fairly normal mandibular growth. *Center.* Six patients showed persistent micrognathia with a severe Class II anterior relationship. *Right.* Three patients, in spite of persistent micrognathia, had fairly good occlusion by virtue of a forward positioning of the mandible and flattening of the gonial angle. Courtesy Randall, Krogman, and Jahina (23).

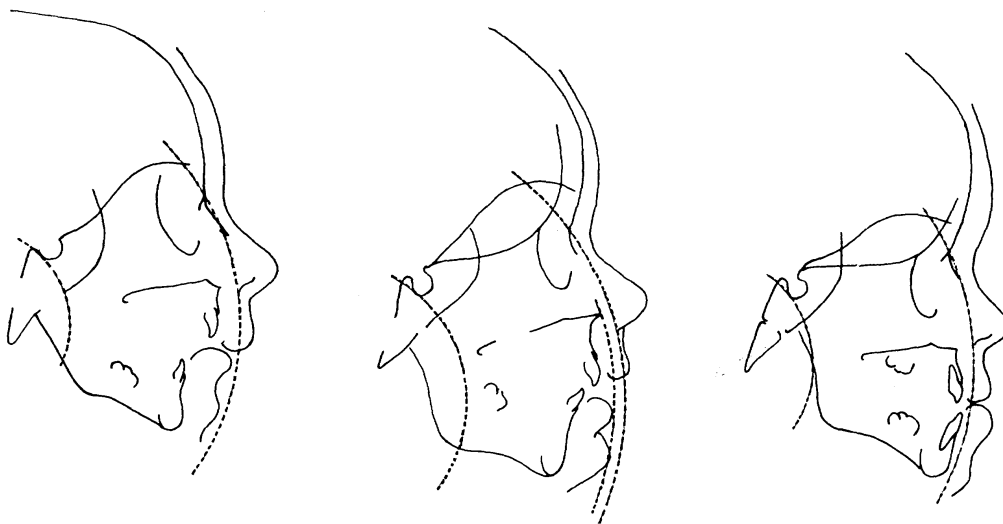


FIGURE 4. Three 'miscellaneous' growth patterns were observed. *Left.* A patient who at six years and seven months of age showed persistent underdevelopment of both the maxilla and the mandible. *Center.* Another patient aged two years and six months with persistent posterior displacement of the mandible and a gonial angle of only  $120^\circ$  instead of an expected angle of about  $137^\circ$ . *Right.* Two patients were seen who developed normal mandibular size, but with an abnormal forward protrusion causing a relative prognathism and an anterior crossbite. Courtesy Randall, Krogman, and Jahina (23).

patient at one year and two months of age had a short mandible, and at four years of age had a mandible of nearly normal size. There were three patients in this group.

The second group of patients showed persistent micrognathia. The patient illustrated in Figure 5 (bottom) showed a marked micrognathia when first studied at five months of age; when seen at eight years and eleven months of age, the underdevelopment was still very marked. There were six patients in this group, and the possibility that any of them will achieve normal mandibular size is unlikely.

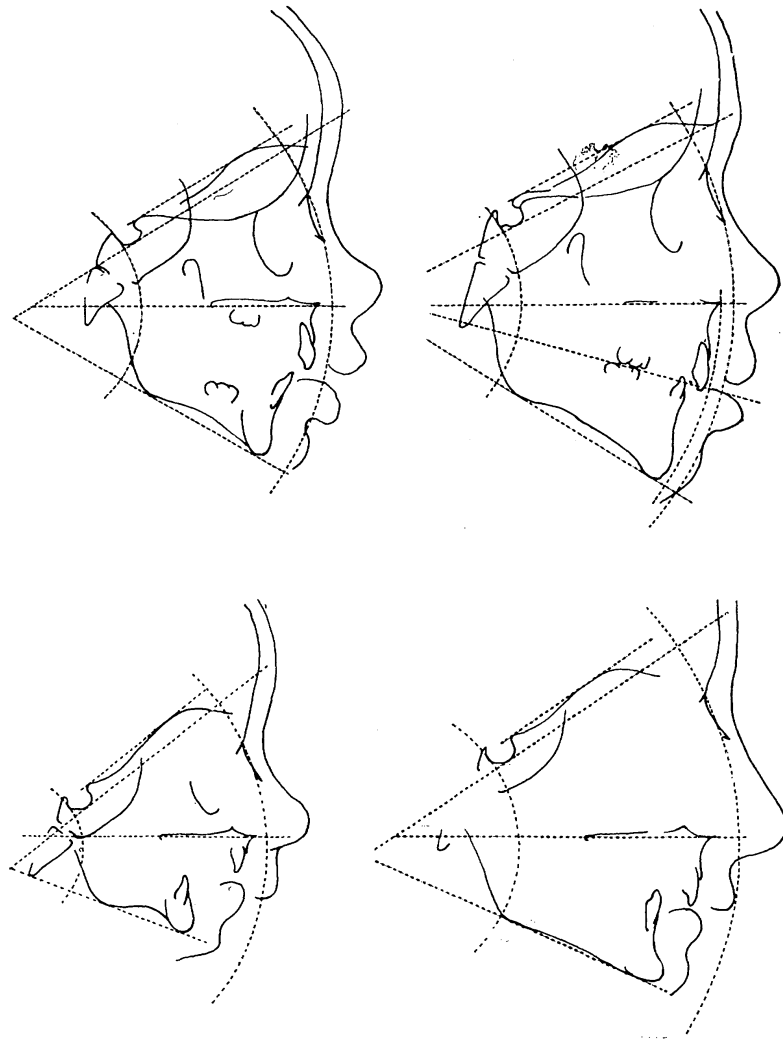


FIGURE 5. *Top.* This patient had a micrognathia as seen on the left at one year and three months of age. Shortly after birth she was unable to maintain an airway except in the face down position. She would have obstruction when lying on her back. The study on the right shows good mandibular size and position at four years and four months of age. *Bottom.* This patient also had a partial airway obstruction shortly after birth; the study on the left was made at five months of age. On the right persistent underdevelopment of the mandible with a severe Class II malocclusion is seen at eight years and 11 months of age. Courtesy Randall, Krogman, and Jahina (23).

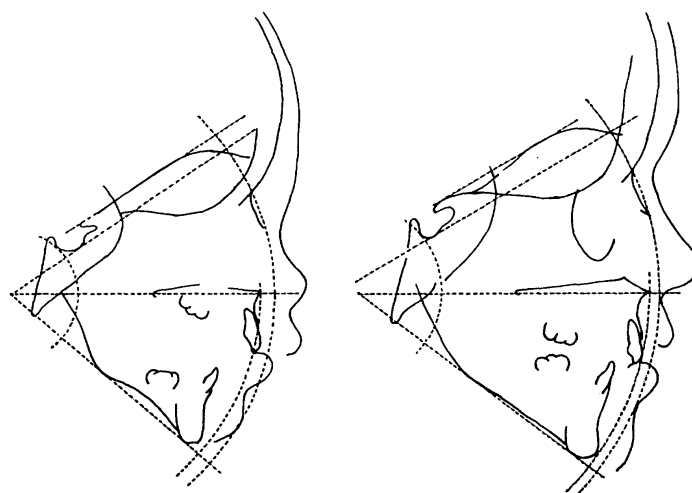


FIGURE 6. The study on the left was made at one year and one month of age and shows marked micrognathia in a patient with upper airway obstruction; while on the right, at two years and four months of age, the mandible is persistently small, but it is thrust forward, flattening the gonial angle and achieving a fairly normal anterior relationship. Courtesy Randall, Krogman, and Jahina (23).

The third group had a similar type of underdevelopment of the mandible but with a tendency for a forward protrusion thus flattening the gonial angle and achieving a fairly normal anterior relationship. The patient illustrated in Figure 6 shows a definite micrognathia at one year and one month of age while at two years and four months of age the protrusion can be seen to be quite marked. The gonial angle measures  $155^\circ$  instead of an expected  $137^\circ$ . There were three patients in this group.

### Discussion

In all likelihood there are several possible etiologies of this condition. This would tend to explain the different deformities noted on the roentgenographic cephalometric examinations at about one year of age and the different patterns of subsequent bony development. It has been stated on numerous occasions that these patients have a 'normal' growth potential of their mandible which was not substantiated by this study<sup>1</sup> (1, 4, 21, 35, 37). A number of the mandibles remained micrognathic and will probably continue to do so. On the other hand, not all of the patients with a receding chin, glossoptosis, and an obstructed airway presented mandibles that were significantly small in size. Indeed, one third of the patients presenting these conditions had mandibles that were distorted in shape and position but not in their overall size. Such a mandible is not truly micrognathic, and it is suggested that the term *retrognathia* (or posterior displacement of the mandible) would be a more accurate term to use.

<sup>1</sup> Personal communication in 1962 with W. M. Krogman.

**Summary**

A brief account of the history of Pierre Robin and his views concerning the syndrome that bears his name have been made. Possible etiologies and the data from the roentgenographic cephalometric studies of 22 patients are discussed. Not all of these mandibles are seen to be truly micrognathic and the term *retrognathia* is suggested as being more fitting. A variety of growth patterns are described, some of which are associated with a persistent underdevelopment of the mandible.

3400 Spruce Street  
Philadelphia 4, Pennsylvania

*Acknowledgment:* The authors acknowledge with great thanks the careful translation of Dr. Pierre Robin's French publications by Mrs. Wendell B. Whitacre.

**References**

1. BEERS, M. D., and PRUZANSKY, S., The growth of the head of an infant with mandibular micrognathia, glossoptosis, and cleft palate following the Beverly Douglas operation. *Plastic reconstr. Surg.*, 16, 189-193, 1955.
2. BENAVENT, W. J., and RAMOS-OLLER, A., Micrognathia: report of twelve cases. *Plastic reconstr. Surg.*, 22, 486-490, 1958.
3. BIGOTTI, A., Casistica: un raro caso di gossoptosi congenita sena ipoposia mandibolare: sindrome di Pierre Robin incomplete. *Minerva Med.*, 50, 3255-3257, 1959.
4. BROMBERG, B. E., PASTERNAK, R., WALDEN, R. H., RUBIN, L. R., Evaluation of micrognathia with emphasis on late development of the mandible. *Plastic reconstr. Surg.*, 28, 537-548, 1961.
5. CALLISTER, A. C., Hypoplasia of the mandible (micrognathy) with cleft plate; treatment in early infancy by skeletal traction. *Amer. J. Dis. Child.*, 53, 1057-1059, 1937.
6. CHAPPLE, C. C., Abnormalities of infants resulting from non-genetic factors. *Postgrad. Med.*, 7, 323-329, 1950.
7. CHAPPLE, C. C., Possible mechanisms of some congenital defects. *Amer. J. Obst. Gyn.*, 70, 711-719, 1955.
8. CHAPPLE, C. C., DAVIDSON, T., The study of the relationship between fetal position and certain congenital deformities. *J. Pediat.*, 18, 483-493, 1941.
9. DAVIS, A. D., and DUNN, R., Micrognathia: suggested treatment for correction in early infancy. *Amer. J. Dis. Child.*, 45, 799-806, 1933.
10. DOUGLAS, B., A further report on the treatment of micrognathia with obstruction by a plastic procedure: results based on reports from 21 cities, 1948-1949. *Plastic reconstr. Surg.*, 5, 113-122, 1950.
11. DOUGLAS, B., The treatment of micrognathia associated with obstruction by a plastic procedure. *Plastic reconstr. Surg.*, 1, 300-308, 1946.
12. ELEY, R. C., and FARBER, S., Hypoplasia of the mandible (micrognathy) as a cause of cyanotic attacks in the newly-born infant: report of four cases. *Amer. J. Dis. Child.*, 39, 1167-1175, 1930.
13. FRASER, G. R., and CALNAN, J. S., Cleft lip and palate: seasonal incidence, birth weight, birth rank, sex, site, associated malformations and parental age. A statistical survey. *Arch. Dis. Child.*, 36, 420-423, 1961.
14. GLADSTONE, R. J., and WAKELY, C. P. G., Defective development of the mandibular arch: the etiology of arrested development and an inquiry into the question of the inheritance of congenital defects. *J. Anat.*, 57, 149-167, 1922-1923.
15. KIEBEL, F., and MALL, F. P. *Manual of Human Embryology*. Philadelphia, Pennsylvania: J. B. Lippincott Company, p. 86, 1962.
16. KISKADDEN, W. S., and DIETRICH, S. R., Review of the treatment of micrognathia. *Plastic reconstr. Surg.*, 12, 364-373, 1953.



17. LAPAGE, C. P., Micrognathia in the new-born. *Lancet*, 1, 323-324, 1937.
18. LLEWELLYN, J. S., and BIGGS, A. D., Hypoplasia of mandible: report of a case with resume of literature and suggestions for modified form of treatment. *Amer. J. Dis. Child.*, 65, 440-444, 1943.
19. LONGMIRE, W. P., and SANFORD, M. C., Stimulation of mandibular growth in congenital micrognathia by traction. *Amer. J. Dis. Child.*, 78, 750-754, 1949.
20. PARMALEE, A. H., Inexpensive incubator for premature infants. *Amer. J. Dis. Child.*, 41, 33-34, 1931.
21. PRUZANSKY, S., and RICHMOND, J. B., Growth of the mandible in infants with micrognathia. Clinical implications. *Amer. J. Dis. Child.*, 88, 29-42, 1954.
22. RANDALL, P., Micrognathia and glossoptosis with airway obstruction Pierre Robin Syndrome. In J. M. Converse (Ed.), *Reconstructive Plastic Surgery*. Philadelphia, Pennsylvania: W. B. Saunders Co., pp. 1452-1462, 1964.
23. RANDALL, P., KROGMAN, W. M., and JAHINA, SOONA, Mandibular growth in Pierre Robin Syndrome. *Transactions of the Third International Congress of Plastic Surgery*. Amsterdam, The Netherlands: Excerpta Medica, pp. 294-299, 1964.
24. ROBIN, P., Backward lowering of the root of the tongue causing respiratory disturbances. *Bull. Acad. Med.*, 89, 37-41, 1923.
25. ROBIN, P., De la physiologie de la tete au sein et de la forme que doit avoir la tetine due biberon. *Bull. Soc. Pediat. Paris*, 27, 54-62, 1929.
26. ROBIN, P., Enfant atteut de glossoptose congenitale eu etat de denutrition par insuffisavee alimentaire tres rapidement ameliovee par le tete orthostatique. *Bull. Soc. Pediat. Paris*, 25, 34-38, 1927.
27. ROBIN, P., *Eumorphi. La Glossoptose, un Grave Danger Pour Nos Enfants*. Paris: G. Doin, 1929.
28. ROBIN, P., Evolution du deflexe glossique des pronogrades aux orthogrades. *Bull. mem. Soc. Med. Paris*, 1, 35-44, 1929.
29. ROBIN, P., Glossoptosis due to atresia and hypotrophy of mandible. *Amer. J. Dis. Child.*, 48, 541-547, 1934.
30. ROBIN, P., Influence of facio-cranio vertebral dysmorphism on health in general. *Bull. Acad. Med.*, 89, 647-648, 1923.
31. ROBIN, P., L'atresie mandibulara congenitale et son role aggravant dans l'evolution du rachitisme et de l'athrepsie. *Bull. Soc. Pediat. Paris*, 26, 85-92, 1928.
32. ROBIN, P., Obituary. *Rev. Stomat.*, 51, 120, 1950.
33. SASSOUNI, V., *The Face in Five Dimensions*. Philadelphia, Pennsylvania: Growth Center Publications, 1960.
34. SHUKOWSKY, W. P., Zur aetiologie des stridor inspriatorius congenitus. *Jahrb. Kinderheilk (Berlin)*, 73, 459-474, 1911.
35. SJOLIN, S., Hypoplasia of mandible as a cause of respiratory difficulties in an infant. *Acta Pediat.*, 39, 255-261, 1950.
36. SWEET, A. M., and KEMSLEY, M., Micrognathia, report of two cases. *Lancet*, 2, 10-12, 1947.
37. WALKER, D. G., *Malformation of the Face*. Edinburgh and London: E. S. Livingstone Ltd., 1961.
38. WOOLF, R. M., GEORGIAD, N. G., and PICKRELL, K. L., Micrognathia and associated cleft palate (Pierre Robin Syndrome). *Plastic reconstr. Surg.*, 26, 199-202, 1960.

### Resource References

- CHAPPLE, C. C., Congenital dislocation of hip in infancy. *J. Pediat.*, 6, 306-315, 1935.
- CHAPPLE, C. C., A duosyndrome of the laryngeal nerve. *J. Dis. Child.*, 91, 14-18, 1956.
- CHAPPLE, C. C., *Nelson's Pediatrics* (7th ed.). Philadelphia, Pennsylvania: W. B. Saunders Co., 1959.
- RANKOW, R. M., and MINERVINI, F., Micrognathia in the new-born: Pierre Robin Syndrome. *Plastic reconstr. Surg.*, 25, 606-614, 1960.
- ROBIN, P., Les deformatione maxillo-faciales et le malpositions des dents. *Presse Med.*, 50, 259, 1942.
- ROBIN, P., Duex observations sur la denutrition des nourrissons attiens de glossoptose congenitale. *J. Med. Paris*, 45, 1052, 1926. Also in *Med. Infantile*, 33, 4-9, 1927.

- ROBIN, P., Evolution du deflexe glossique des pronogrades aux orthogrades. *J. Med. Paris*, 48, 880-884, 1929.
- ROBIN, P., La glossoptose chez le nourrisson, sa guerison par une nouvelle maniere de faire teter. *J. Med. Paris*, 45, 1011, 1296. Also in *Med. Infantile*, 32, 366-376, 1926.
- ROBIN, P., Presentation d'enfants pour demontrer le vole de la glossoptose dans certains desequilibres de la vie organo-vegetative et physique. *Bull. Soc. Pediat. Paris*, 25, 267-272, 1927.
- ROBIN, P., Reeducation morpho-fonctionnelle du massif facio-cranio vertebraal. *Evolution Ther. Med. Chir.*, 7, 525-532, 1926.
- ROBIN, P., De la reeducation respiratoire chez le nourrisson par la tete physiologique. *Evolution Ther. Med. Chir.*, 7, 521-524, 1926.
- ROBIN, P., and SAMANA, L., Lutte contre la glossoptose. *Marseille Med.*, 2, 427-439, 1935.
- SCHWARTZ, L., Ateliosis of the mandibular arch: critical comment on glossoptosis, the syndrome of Pierre Robin., *Arch. Otolaryng.*, 31, 491-501, 1940.